



VCU

Virginia Commonwealth University
VCU Scholars Compass

Theses and Dissertations

Graduate School

2001

Alveolar Ridge Dimension Analysis Following Socket Preservation Using Clinical Assessment and Cone Beam Computed Tomography (CBCT).

Sayward Duggan
Virginia Commonwealth University

Follow this and additional works at: <https://scholarscompass.vcu.edu/etd>



Part of the [Dentistry Commons](#)

© The Author

Downloaded from

<https://scholarscompass.vcu.edu/etd/2433>

This Thesis is brought to you for free and open access by the Graduate School at VCU Scholars Compass. It has been accepted for inclusion in Theses and Dissertations by an authorized administrator of VCU Scholars Compass. For more information, please contact libcompass@vcu.edu.

School of Dentistry
Virginia Commonwealth University

This is to certify that the thesis prepared by Sayward Edwards Duggan, D.D.S., entitled ALVEOLAR RIDGE DIMENSION ANALYSIS FOLLOWING SOCKET PRESERVATION USING CLINICAL ASSESSMENT AND CONE BEAM COMPUTED TOMOGRAPHY (CBCT) has been approved by her committee as satisfactory completion of the thesis requirement for the degree of Master of Science in Dentistry

Thomas C. Waldrop, D.D.S., M.S., Thesis Director, Virginia Commonwealth University
School of Dentistry

John C. Gunsolley, D.D.S., M.S., Committee Member, Virginia Commonwealth
University School of Dentistry

Robert Sabatini, D.D.S., M.S., Committee Member, Virginia Commonwealth University
School of Dentistry

Thomas E. Koertge, D.M.D., Ph.D., Committee Member, Virginia Commonwealth
University School of Dentistry

Thomas C. Waldrop, D.D.S., M.S., Residency Program Director Department of
Periodontics, Virginia Commonwealth University School of Dentistry

Harvey A. Schenkein, D.D.S., Ph.D., Chairman Department of Periodontics, Virginia
Commonwealth University School of Dentistry

Laurie C. Carter D.D.S., Ph.D., Director of Advanced Dental Education, Virginia
Commonwealth University School of Dentistry

Dr. F. Douglas Boudinot, Dean of the Graduate School
May 2, 2011

© Sayward Edwards Duggan 2011

All Rights Reserved

ALVEOLAR RIDGE DIMENSION ANALYSIS FOLLOWING SOCKET
PRESERVATION USING CLINICAL ASSESSMENT AND CONE BEAM
COMPUTED TOMOGRAPHY (CBCT)

A thesis submitted in partial fulfillment of the requirements for the degree of Masters of
Science in Dentistry at Virginia Commonwealth University.

By

SAYWARD EDWARDS DUGGAN
Bachelor of Arts, University of Virginia, 2001
Doctor of Dental Surgery, Virginia Commonwealth University School of Dentistry, 2006

Director: THOMAS C. WALDROP, D.D.S., M.S.
RESIDENCY PROGRAM DIRECTOR, DEPARTMENT OF PERIODONTICS

Virginia Commonwealth University
Richmond, Virginia
June 2011

Acknowledgements

Thank you to my research committee members for providing the guidance and mentorship to bring this study to fruition. A special thanks to my fellow graduate periodontal residents for their support in recruiting patients for this study. Also, thank you to the Alexander Fellowship grant for providing funding towards this study. Finally, a special thanks to my husband, Andy and son, Jack for their endless love and support.

Table of Contents

	Page
Acknowledgements.....	ii
List of Tables	iv
List of Figures.....	v
Abstract.....	vi
Chapter	
1 Introduction.....	1
2 Methods and Materials.....	7
Patient Selection.....	7
Surgical Protocol	8
Follow up.....	9
Statistical Analysis	10
3 Results.....	11
4 Discussion.....	15
5 Conclusions.....	18
References.....	20

List of Tables

	Page
Table 1: Characteristics of a Study Population.....	24
Table 2: Initial Clinical and Radiographic Ridge Dimensions.....	25
Table 3a: Correlations between Clinical and Radiographic Measurements at the Initial Appointment.....	26
Table 3b: Correlations between Clinical and Radiographic Measurements at Follow up Appointment (3-4 Months).....	27
Table 4: Changes in Clinical and Radiographic Ridge Dimensions over 3-4 Months.....	28
Table 5: Initial and Change over 3-4 Months in Radiographic Vertical Occlusion Dimension Based on Reason for Extraction.....	29

List of Figures

	Page
Figure 1:	30
Figure 2:	31
Figure 3:	32
Figure 4:	34
Figure 5:	35

Abstract

ALVEOLAR RIDGE DIMENSION ANALYSIS FOLLOWING SOCKET PRESERVATION USING CLINICAL ASSESSMENT AND CONE BEAM COMPUTED TOMOGRAPHY (CBCT)

By Sayward Edwards Duggan, D.D.S.

A thesis submitted in partial fulfillment of the requirements for the degree of Masters of Science in Dentistry at Virginia Commonwealth University.

Virginia Commonwealth University, 2011

Major Director: Thomas C. Waldrop, D.D.S., M.S.
Residency Program Director, Department of Periodontics

PURPOSE: Extraction of a tooth can lead to alveolar ridge resorption which can be minimized by socket preservation. The aim of this study is to analyze vertical and horizontal alveolar ridge dimensions clinically and by CBCT immediately following extraction and 3-4 months following socket preservation.

METHODS: The preserved group (P) consisted of 20 patients with 1-2 non-molar teeth requiring extraction with socket preservation, while the control group (C) consisted of 5 patients requiring extraction alone. An acrylic stent was fabricated presurgically in order to measure vertical and horizontal ridge dimensions clinically and radiographically immediately following extraction and 3-4 months following socket preservation.

RESULTS: Overall, P sites gained ridge height and lost minimal ridge width over 3-4 months, while C sites lost both ridge height and width. Preserved sites in which the teeth were

extracted due to caries had the most significant gain in the radiographic vertical occlusal dimension (RVO). Overall, high correlations were found between the clinical and radiographic measurements at the initial surgery and at the 3-4 month follow up.

CONCLUSIONS: The preserved group had minimal ridge resorption and more socket bony fill when compared to the non-preserved group 3-4 months following tooth extraction, especially when the tooth was extracted due to caries. Additionally, the CBCT can be a useful diagnostic tool to evaluate socket preservation healing, as it compares well to clinical assessments of socket healing.

Introduction

Alveolar ridge deformation can result from the extraction of a tooth, as it is due to both hard and soft tissue loss. This deformation, or resorption, is a functional and esthetic concern, especially in the area of restorative implant and prosthetic dentistry.^{1,2} Cone beam computed tomography (CBCT) provides a three-dimensional image of the dental and maxillofacial areas. The CBCT is a useful tool for evaluation of alveolar ridge sites and can be used to locate anatomical structures, support diagnostic implant planning, and function as a guide for dental surgery. Reliable linear measurements of dentomaxillofacial structures and volume estimates can be produced from this type of imaging, thereby indicating that the CBCT may have the potential to evaluate socket preservation healing.^{3,4}

Following the extraction of a tooth, the socket begins healing by secondary intention. Specific microvascular changes, as well as a bone formation pattern develop prior to bone remodeling.⁵ An *initial angiogenic* phase has been suggested, occurring within the first week following tooth extraction. Ohta proposed that fragments of blood vessels from the residual periodontal ligament leak into the socket, forming aggregates of immature fibroblasts. This begins at the socket fundus, forming granulation tissue that consists of immature fibroblasts and capillaries.⁶ Histological observations from bone blocks taken from fresh extraction sites reveal that at day 7-8 new bone is forming within the marrow vascular spaces adjacent to the socket wall, but not in the socket itself. New bone formation within the extraction socket first appears 10 days following tooth extraction, along the lateral wall of the socket. Bone continues to remodel

within the tooth socket at day 19 post-extraction and bone remodeling continues for 4-6 months following tooth extraction.^{6,7}

Alveolar ridge deformation occurs by resorption of the buccal and lingual external socket walls. In dried skull studies, Pietrokovski found that following extractions in both the maxillary and mandibular arches, more resorption occurs from the buccal aspect of the ridge.^{2,8} According to Otto, loss of ridge width is greater than loss of ridge height, due to the increase resorption of the buccal aspect of both the maxillary and mandibular alveolar process.⁹ Schropp *et al* found clinically and radiographically, at 12 months post-extraction, a 50% reduction in alveolar ridge width (from 12mm to 5.9mm), with two-thirds of the reduction occurring in the first 3 months. Ridge height, however, only slightly decreased (< 1mm).¹⁰ Ridge width resorption may increase in severity when the buccal plate of bone is thin or absent.¹¹ McCall *et al* reported 40%-60% loss of original bone height and width within 2 years following multiple extractions.¹² A systematic review assessing alveolar bone dimensional changes of post-extraction sockets in humans, clinically and radiographically, concludes that the loss of ridge width averages 3.87 mm, while the loss of ridge height ranges from 1.67 to 2.03 mm.¹³

A recent study has suggested that the width of the buccal wall may affect the pattern of bony resorption.¹⁴ Spray *et al* found that 2mm of buccal wall reduces buccal bone loss around implants placed in healed sites.¹⁵ A multicenter clinical study of immediate implant placement examined the width of the buccal and palatal walls in extraction sites. For anterior sites (canine-canine), the mean width of the buccal wall was 0.8 mm, while for posterior sites (premolars); the mean width of the buccal wall was 1.1 mm. 87% of the anterior sites had a buccal wall width of \leq

1mm; while 59% of the posterior sites had a buccal wall width of ≤ 1 mm.¹⁶ Clinical guidelines established by a panel of master clinicians agreed that a minimum of 2mm of buccal bony wall is necessary for a soft and hard tissue esthetic outcome for implant placement and restoration.¹⁷

Many hard and soft tissue regenerative options are available for preserving and correcting ridge defects, including socket preservation. These techniques are designed to minimize ridge resorption and soft tissue recession, as well as maximize formation of bone. Socket preservation, with the use of grafted material, provides space maintenance in order to prevent tissue collapse and maintain a healthy architecture for future restorative options. In extraction sites augmented with bovine bone, Nevins *et al* found a decrease in alveolar bone height loss.^{9,18} Fickl *et al* compared socket preservation with bovine bone and a non-resorbable membrane versus bovine bone with a connective tissue graft versus no socket preservation treatment in a pre-molar extraction site in beagle dogs. The two socket preservation techniques had significantly less buccal width resorption than the site without socket preservation.¹⁹ Augmentation of an extraction socket with bone grafting can result in preservation of 85% of the initial alveolar ridge dimensions.²⁰ These studies have suggested that socket preservation is one technique that will minimize ridge resorption, thereby preserving ridge dimensions.

Multiple socket preservation techniques are available, and no technique is considered better than another. Grafting materials include autogenous bone, demineralized freeze-dried bone allografts (DFDBA), freeze-dried bone allografts (FDBA), xenografts, bioactive glass, hydroxyapatite and calcium sulphate. Many socket preservation studies have indicated treatment with a barrier membrane in addition to bone grafting. Barrier membranes include expanded

polytetrafluoroethylene (ePTFE), collagen, polyglycolic acid, and polyglactin 910; these can be resorbable or non-resorbable. In a split mouth prospective study, Lekovic and colleagues found after six months, less change from baseline to six months in regards to the external vertical measurement (ridge height) and horizontal measurement (ridge width) in the socket preserved group versus the control group. More change was found from baseline to six months in the internal vertical measurement (socket bone fill) in the socket preserved group versus the control group. The socket preservation technique in this study consisted of a bioabsorbable membrane (glycolide and lactide polymers) only.^{1,2,9,21} Iasella *et al* found that non-molar extraction and socket preservation with FDBA and a collagen membrane resulted in a gain of 1.3 ± 2.0 mm of ridge height, while extraction without preservation lead to a loss of 0.9 ± 1.6 mm ridge height. In addition, although both groups loss ridge width, the extraction and socket preservation loss 1.6mm less than the extraction alone group.²²

Multiple studies have evaluated the efficacy and accuracy of different radiographic methods used for clinical applications of dentistry. Intraoral films, such as bite-wings and periapicals provide a two-dimensional image, while computed tomography produces a three-dimensional image.²³ The CBCT obtains this image by using a two-dimensional detector to scan the head, rather than stacking multiple slices together, as the conventional CT scanner does. This allows for a more efficient, more economical, and lower energy output image.²⁴ In addition to these benefits, the CBCT does not expend high radiation doses. The CBCT has a radiation dose of 0.585 mSv, which is below doses of the conventional CT scanner, but above doses of conventional dental radiographs. Cortical width and integrity, as well as cancellous bone have been identified clearly in the cross-sectional images produced by the CBCT. Vertical distances measured from

reference points on cadaver mandibles can also accurately be measured using the CBCT, which may be useful in certain clinical applications.^{24,25}

Alveolar ridge height and width can also be analyzed more accurately with CBCT than traditional dental films. Bolin *et al* compared mean bone heights of posterior edentulous areas in panoramic and tomographic radiographs; panoramic radiographs overestimated the available alveolar ridge height.²⁶ Reddy *et al* also found that the CT is more accurate at determining alveolar ridge height than intraoral dental films and provides buccal-lingual width analysis.²⁷ Fuhrmann *et al* also demonstrated that high resolution computed tomography (HR-CT) was useful in evaluating buccal and lingual width of bone. A comparison of HR-CT with standard dental radiographs resulted in an average underestimation of 0.6mm of horizontal alveolar bone loss in the dental radiographs and a 0.2mm overestimation of bone loss in the HR-CT images; vertical bone loss was underestimated by 2.2mm and 0.2mm in dental radiographs and HR-CT images, respectively.²⁸ In clinically assessing alveolar bone grafting prior and after dental implant placement and in orthodontic treatment of cleft-adjacent teeth, Hamada *et al* determined that CBCT provided accurate measurements of the alveolar ridge vertical height and buccal-palatal ridge width with the measuring device provided in the film.²⁹ These past studies indicate that the CBCT is a highly accurate method of analyzing ridge dimensions, including ridge height and width.

As stated earlier, alveolar ridge resorption is a functional and esthetic concern, especially in the area of restorative implant and prosthetic dentistry. Both clinical and radiographic assessments are especially critical during presurgical treatment planning involving implant placement for

future restorative outcome. A review of available literature reveals gaps that exist in the comparative diagnostic utility associated with traditional clinical measurements and measurements obtained using technologically advanced radiographic techniques associated with socket preservation. Therefore, in an effort to compare findings clinically and with the most up-to-date radiographic tool (CBCT) following socket preservation, the aim of this study is to analyze vertical and horizontal alveolar ridge dimensions clinically and by cone beam computed tomography (CBCT) immediately following extraction and 3 to 4 months following socket preservation.

Methods and Materials

Patient Selection

The Institutional Review Board of Virginia Commonwealth University reviewed and approved this research protocol. Patients were recruited from the Virginia Commonwealth University School of Dentistry from July 2009-November 2010. All subjects were screened and written informed consent was obtained based on the inclusion criteria. In the preserved group (P), twenty patients having 1 or 2 non-molar teeth requiring extraction followed by socket preservation were selected. The control group (C) consisted of five patients having 1 or 2 non-molar teeth requiring extraction not followed by socket preservation. Fewer patients were selected in the control group due to the difficult acquisition of patients willing to return for a follow up appointment. All extraction sites had to be bordered by at least one tooth.²² Patient exclusion criteria included: non-controlled systemic conditions that affect the periodontium (e.g. diabetes and immunodeficiencies); known allergy to freeze-dried bone allograft or collagen membranes; required antibiotic prophylaxis; current smokers; more than 50% of the buccal plate missing at the time of extraction; and molar extraction sites.

After eligibility criteria were met, an alginate impression was taken at the treatment planning appointment. Between the treatment planning appointment and the surgical appointment, an acrylic stent was fabricated based on the cast model with 6 radiopaque markers: mesiobuccal, distobuccal, mesiolingual, distolingual, occlusal, and mid-buccal. This stent was used to obtain both clinical and radiographic measurements at the initial surgical appointment and 3-4 months

following the surgery. The pre-fabricated stent allowed for accurate replications of measurements from the surgical appointment to the 3-4 month follow up appointment.

Surgical Protocol

After local anesthesia administration and immediately following atraumatic extraction with minimal flap reflection and debridement of the socket, clinical measurements were taken of the extraction site from vertical and horizontal dimensions listed above using a UNC periodontal probe (nearest 1mm) and Weiss Modified Castroviejo caliper (nearest 1mm) with the stent in place. The vertical measurements include: mesiobuccal (CVMB), distobuccal (CVDB), mesiolingual (CVML), distolingual (CVDL), and occlusal (CVO). The horizontal measurements include the thickness of the buccal plate at the mid-buccal alveolar crest (CB1) and mid-buccal 5 mm below the alveolar crest (CB5). Additionally, the buccal-lingual alveolar width was clinically measured mid-buccal alveolar crest (CBL1) and mid-buccal 5 mm below the alveolar crest (Figures 1 and 2). Following clinical measurements, a CBCT image was taken using the CBCT machine with the stent in place. The information was formatted to the Keystone Easyguide© software and measurements were taken of the alveolar crest vertical height from five different points (Figure 3)---mesiobuccal (RVMB), distobuccal (RVDB), mesiolingual (RVML), distolingual (RVDL) line angles, and occlusal (RVO). The thickness of the alveolar buccal plate was measured at the mid-buccal alveolar crest (RB1) and mid-buccal 5 mm below the alveolar crest (RB5). Additionally, the alveolar buccal-lingual ridge width of the extracted tooth was also recorded using CBCT at the mid-buccal alveolar crest (RBL1), and mid-buccal 5 mm below the alveolar crest (RBL5) (Figure 3).

After these measurements were recorded, the preserved group (P) had freeze-dried mineralized human bone allograft (Lifenet Oragraft®) placed and condensed into the socket with a layer of bioabsorbable collagen membrane (Keystone Dynamatrix®) covering the graft. A non-resorbable figure-8 suture was used to hold the graft in place (Figure 4). In the incidence of a buccal wall bony dehiscence, a bioabsorbable collagen membrane was first placed against the buccal wall prior to grafting. If the buccal wall was less than 50% present at the time of socket preservation, the site was excluded from the study.³⁰ Following measurements in the control group (C); a resorbable collagen plug (Zimmer Collaplug®) was placed into the socket. A resorbable figure-8 suture was used to secure the plug (Figure 5).

Both the preserved and control patients were given standard post-operative instructions verbally and written. The P group was given 500 mg of Amoxicillin 3 times daily for 10 days following the procedure; in the case of Penicillin allergy, the patient was given 150 mg of Clindamycin 4 times daily for 10 days. The preserved and control patients were both given analgesics, including narcotics on an individual basis. All patients were given a 0.12% chlorhexidine gluconate mouth rinse twice daily for two weeks following the surgery. Additionally, all patients were seen at a two week post-operative appointment for suture removal and to ensure adequate healing.

Follow up

The patients returned 3-4 months following surgery. The same stent was used to repeat the radiographic and clinical measurements. The clinical measurements were taken by bone sounding after local anesthesia administration. The radiographic measurements were taken from

a new CBCT scan to evaluate the surgical site for restorative treatment. The radiographic and clinical measurements at the 3-4 month follow up appointment were compared to the radiographic and clinical measurements taken at the surgical appointment for changes in alveolar ridge height and width.

Statistical Analysis

This is a two-group pre-post experimental design using two measurement methods—clinical and radiographic (CBCT). The pre-post change was compared between the two groups using repeated-measures one-way Analysis of Variance (ANOVA). This design also tested whether the change is different between the two measurement methods using pairwise correlations.

Results

A total of 29 patients participated in this study, 23 subjects represented the preserved group (P), while 6 subjects represented the control group (C). Three patients from the P group were excluded from the study; one patient had over 50 % of the buccal plate missing at the time of extraction, one subject did not return for the follow up appointment, and one patient moved to the control group prior to the initial surgical appointment. One patient from the C group signed the consent form, but never returned for the initial surgical appointment. Therefore, 19 patients represented the preserved group due to one patient contributing two extraction sites to the study, while 5 patients made up the control group.

Table 1 shows the distribution of age, gender, race, tooth type, and reason for extraction among the study population. The mean age in the preserved group was 54 years, while the mean age in the control group was 64 years. Females represented 45% and males 55% in the P group, while females represented 60% and males 40% in the C group. African-Americans constituted 10% and 60%, while Caucasians represented 90% and 40% of the P group and C group, respectively. This was the only statistically significant characteristic difference between the preserved and control groups ($p=0.037$). Maxillary incisors (centrals, laterals, and canines) accounted for 25% of the P group and 40% of the C group, while maxillary premolars (first and second premolars) constituted 55% of the P group and 20% of the C group. Mandibular premolars (first and second premolars) represented 20% and 40%, in the preserved and control group, respectively. Reasons for extraction included non-restorable caries and periodontal disease. One subject with a failed apicoectomy, as well as one subject with a vertical root fracture was included in the non-restorable caries category. 80% of teeth in the P group were extracted due to non-restorable

caries, while 20% were extracted due to periodontal disease. In the C group 40% of the teeth extracted had non-restorable caries, while 60% had periodontal disease.

Table 2 shows the initial ridge dimensions measured clinically and radiographically immediately following tooth extraction. The vertical and horizontal ridge dimensions are noted for both the preserved and control groups. The clinical and radiographic initial ridge dimension measurements do not significantly differ from one another. In fact, as represented in Table 3a, the initial clinical and radiographic measurements are highly correlated. The clinical vertical ridge measurements are highly correlated ($R=0.87$) with the radiographic vertical ridge measurements. The initial ridge width, or horizontal clinical measurements at the mid-buccal alveolar crest and mid-buccal 5 mm below the alveolar crest are highly correlated ($R=0.89$) with the radiographic horizontal ridge dimensions. Table 3b demonstrates the correlations between the clinical and radiographic alveolar ridge dimensions at 3-4 months follow up. At follow up, the vertical ridge measurements are once again highly correlated ($R= 0.86$) with the radiographic vertical measurements. The clinical and radiographic mid-buccal ridge width measurements at follow up are highly correlated ($R=0.71$), while clinical and radiographic mid-buccal measures 5 mm below the alveolar crest are moderately correlated ($R=0.56$).

The changes in ridge dimensions from the initial surgical appointment to the three month follow up appointment are represented in both the preserved sites and the control sites in Table 4.

Vertical and horizontal ridge changes were calculated by subtracting the mean three month measurement from the mean initial measurement. A negative number indicates a gain in bone for the vertical clinical and radiographic measurements, while a positive number indicates a loss of bone. The change in the clinical vertical mesiobuccal ($CVMB= -0.30\pm 1.30$) and distobuccal

(CVDB= -0.65 ± 1.18), as well as the radiographic vertical mesiobuccal (RVMB= -0.17 ± 1.51) dimensions gained bone in the P sites. In the C sites, the CVMB= 0.80 ± 0.45 and RVMB= 0.35 ± 0.86 , while the CVDB and RVDB were 0.60 ± 1.16 and 0.90 ± 0.98 , respectively. The change in CVMB between the preserved and control sites approached significance ($p=0.08$), while the change in CVDB between the P and C sites was statistically significant, $p=0.044$. The clinical (CVO) and radiographic vertical occlusal (RVO) dimension changes in the preserved sites were -9.30 ± 3.79 and -8.96 ± 3.13 , respectively, while the CVO was -5.60 ± 3.51 and RVO= -4.95 ± 1.60 in the control sites. The change in RVO was highly significant ($p=0.01$) between the P and C sites, while the change in CVO approached significance ($p=0.06$).

The changes in horizontal dimension or ridge width measurements are also demonstrated in Table 4. For these clinical and radiographic measures, a negative number indicates a loss of bone, while a positive number indicates a gain in bone. The buccal plate lost width, measured radiographically, mid-buccal at the alveolar crest (RB1= -0.31 ± 0.4 and -0.66 ± 0.28) and 5 mm the alveolar crest (RB5= -0.25 ± 0.59 and -0.25 ± 0.19) in the preserved and control sites, respectively. Overall, the C sites clinically (CBL1= -2.40 ± 1.52), as well as radiographically (RBL1= -1.26 ± 0.79), lost more buccal-lingual width at the alveolar crest than the P sites (CBL1= -0.40 ± 3.55 and RBL1= -0.16 ± 3.32). The preserved sites gained some ridge width 5 mm below the alveolar crest clinically and radiographically, 0.25 ± 4.45 and 0.63 ± 3.92 , while the control sites lost ridge width (CBL5= -1.80 ± 1.10 and RBL5= -0.71 ± 0.65).

The change in the radiographic vertical occlusion (RVO) dimension was evaluated between treatment groups, P and C, based on reason for tooth extraction. The change in RVO was significantly different ($p=0.05$) between the preserved sites (-9.89 ± 2.50) and the control sites

(-6.00±2.56) if the tooth was extracted due to non-restorable caries. If the tooth was extracted due to periodontal disease, the change in RVO was -5.26±2.80 in the P sites and -4.25±0.16 in the C sites. This change in RVO was not significantly different between the preserved and control sites if the tooth was extracted due to periodontal disease.

Discussion

The aim of this study was to analyze vertical and horizontal alveolar ridge dimensions clinically and by cone beam computed tomography immediately following extraction and 3 to 4 months following socket preservation. The results indicate that the initial alveolar ridge dimensions in both the preserved and control sites were similar; there were no statistical differences between sites. The change in the external alveolar ridge height from the initial extraction to the three month follow up indicates that the preserved sites gained about 0.25 mm to 0.5 mm of height along the buccal aspect of the socket wall while the control sites lost about 0.5 mm to 0.75mm of ridge height. Iasella *et al* reported similar findings in their study, stating that socket preservation resulted in about a 1 mm gain of ridge height, while extraction alone had a loss of about 1 mm in ridge height.²² In our study, the internal ridge height dimension, or socket bony fill when measured radiographically was statistically different between the preserved and non-preserved sites; the preserved sites gained approximately 9 mm of height while the control sites gained about 5 mm of height. This dimensional change is consistent with previous studies as well; Lekovic *et al* found the most amount of change in the internal vertical measurement (socket bony fill) from baseline to six months in a split mouth study comparing control versus preserved sites.²¹

When analyzing the change in alveolar ridge width in our study, both the preserved and control sites lost ridge width at the alveolar crest; the preserved sites lost about 0.25 mm, while the control sites lost about 1.5 mm. The preserved sites gained about 0.25 mm to 0.5 mm in ridge width 5 mm below the crest while the control sites lost about 1 mm in ridge width at this dimension. Iasella *et al* also found in a previous study that both the preserved and control sites

lost ridge width, but the socket preserved sites lost less ridge width overall than the control sites.²²

The changes in external alveolar ridge height, internal ridge height, and ridge width in our study were evaluated both clinically and radiographically using the CBCT. Changes in ridge dimensions over 3-4 months were not only compared between the preserved and control sites, but within each site at both the initial and follow up appointment. These clinical and radiographic findings were then compared to determine if a correlation existed between the two measures. Our study found that the correlations are high and statistically significant ($p=0.05$) when comparing the clinical (measured by bone sounding) and radiographic (measured by CBCT) measurements at both the initial extraction and at 3-4 month follow up. The only moderate correlation was at the time of extraction between the clinical and radiographic buccal plate width at the alveolar crest and 5 mm below the alveolar crest. The overall high correlations between these two tools of measurement is not surprising as previous studies have found that the CT is highly accurate at determining the alveolar ridge height and width, especially when comparing CT images to standard dental radiographs.^{27,28} Additionally, bone sounding is also a highly accurate clinical assessment of alveolar bone height.³¹ Clinical and radiographic measurements in our study were also standardized due to the fabrication and utilization of an acrylic stent.

The outcomes of our study depended on a number of variables, including the socket preservation technique used. While numerous socket preservation techniques are available, our study standardized the preservation technique in order to decrease variability. Freeze-dried human allograft and a bio-absorbable collagen membrane was placed into the extraction site based on the study by Iasella, in which there was gain in ridge height and minimal loss of ridge width in preserved sites using this technique.²² Although the preservation technique in our study was

standardized, a number of other factors may have played a role in the socket preservation outcome. These factors include: reason for tooth extraction (non-restorable caries or periodontal disease), trauma from extraction, prominent tooth roots, damage or dehiscence in the buccal plate, or experience of the practitioner. Steps taken in this study in order to reduce these factors included atraumatic tooth extraction with a majority of the buccal plate intact and minimal flap reflection.

Additionally, our study evaluated statistically whether the reason for tooth extraction played a role in the socket preservation outcome. Teeth were extracted due to either periodontal disease or non-restorable caries. The radiographic internal ridge height (socket bony fill) was significantly greater in the preserved sites compared to the control sites in teeth that were extracted due to non-restorable caries. The socket bony fill was not significantly different between the preserved and control sites in teeth that were extracted due to periodontal disease. One explanation for the difference between socket bony fill in sites where teeth were extracted due to caries versus due to periodontal disease may be the small sample size of the control group, which consisted of only 3 patients with periodontal disease. Previous studies have suggested that ridge preservation with bone grafting and a bioabsorbable membrane in patients with severe periodontitis resulted in adequate ridge width and height for implant placement.³² While this study did not find a significant difference in preserved versus non-preserved periodontally involved teeth, the preserved sites still tended to gain approximately 1mm more of socket bony fill, thereby highlighting the importance of socket preservation regardless of reason for extraction.

Conclusions

In conclusion, there was an overall high correlation between clinical and radiographic measurements at both the initial and follow up appointment and a moderate correlation between the clinical and radiographic buccal plate width (at the alveolar crest and 5 mm below the crest). The overall high correlations between these two tools of measurement highlight the importance of evaluating socket preservation healing both clinically and with the CBCT, especially for implant treatment planning and future restorative outcomes.

Preserved sites gained approximately 0.25 mm to 0.5 mm of external alveolar ridge height on the buccal aspect of the socket wall while the control sites lost an average of 0.5 mm to 0.75 mm of ridge height; the clinical vertical distal buccal (CVDB) measure was significantly different value between P and C sites. Preserved sites gained approximately 9 mm of internal ridge height (socket bony fill) while the control group gained about 5 mm of height; this radiographic vertical occlusal (RVO) measure was significantly different between P and C sites. Both the preserved and control sites lost alveolar ridge width at the alveolar crest (CBL1 and RBL1); the preserved sites lost about 0.25 mm, while the control sites lost approximately 1.5 mm. Preserved sites gained about 0.25 mm to 0.5 mm in ridge width 5 mm below the crest (CBL5 and RBL5) while the control sites lost about 1 mm in ridge width.

The radiographic internal ridge height (socket bony fill) was significantly greater in preserved sites extracted due to non-restorable caries when compared to non-preserved sites. No significant differences were found in socket bony fill in preserved versus non-preserved sites extracted due to periodontal disease.

VITA

Sayward Edwards Duggan was born on September 18, 1979 in Roanoke, Virginia, and is an American Citizen. She graduated from Patrick Henry High School in Roanoke, Virginia in 1997. She received her Bachelor of Arts from the University of Virginia in Charlottesville, Virginia in 2001. She received her Doctorate of Dental Surgery from Virginia Commonwealth University in Richmond, Virginia in 2006. She received a General Practice Residency Certificate from the University of Virginia in Charlottesville, Virginia in 2008.

Literature Cited

1. Irinakis T, Tabesh M. Preserving the socket dimensions with bone grafting in single sites: an esthetic surgical approach when planning delayed implant placement. *J Oral Implantol* 2007; 33: 156-163.
2. Darby I, Chen S, De Poi R. Ridge preservation: what it is and when should it be considered. *Aust Dent J* 2008; 53: 11-21.
3. Agbaje JO, Jacobs R, Maes F, Michiels K, van Skenberghe D. Volumetric analysis of extraction sockets using cone beam computed tomography: a pilot study on ex vivo jaw bone. *J Clin Periodontol* 2007; 34: 985-990.
4. Lascala CA, Panella J, Marques MM. Analysis of the accuracy of linear measurements obtained by cone beam computed tomography (CBCT-NewTom). *Dentomaxillofac Radiol* 2004; 33: 291-294.
5. Misch C. Bone Augmentation for Implant Placement: Keys to Bone Grafting. Implant Surgery Textbook. 451-464.
6. Ohta Y. Comparative changes in microvascular and bone during healing of implant and extraction sites. *J Oral Implant* 1993; 3: 184-198.
7. Boyne, P. Osseous repair of the postextraction alveolus in man. *Oral Surg Oral Med Oral Pathol* 1966; 21: 805-813.
8. Pietrokovski J. The bony residual ridge in man. *J Prosthet Dent* 1975; 34: 456-462.
9. Otto M. Socket Preservation. *SADJ* 2006; 61: 366-368.
10. Schropp, L, Wenzel A, Kostopoulos L, Karning T. Bone healing and soft tissue contour changes following single-tooth extraction: A clinical and radiographic 12-month prospective study. *Int J Periodontics Restorative Dent* 2003; 23: 313-323.
11. Misch CE, Silc JT. Socket grafting and alveolar ridge preservation. *Dentistry Today* 2008; 27: 146-150.
12. McCall RA, Rosenfeld AL. Influence of residual ridge resorption patterns on implant fixture placement and tooth position. Part 1. *Int J Perio and Restorative Dent* 1991; 11: 8-23.
13. Van der Weijden F, Dell'Acqua F, Slot DE. Alveolar bone dimensional changes of post-extraction sockets in humans: a systematic review. *J Clin Periodontol* 2009; 36: 1048-1058.
14. Ferrus J, Cecchinato D, Pjetursson BE, Lang NP, Sanz M, Lindhe J. Factors influencing ridge alterations following immediate implant placement into extraction sockets. *Clinical Oral Implants Research* 2010; 21: 22-29.

15. Spray JR, Black CG, Morris HF, Ochi S. The influence of bone thickness on facial marginal bone response: stage I placement through stage 2 uncovering. *Annals Of Periodontology* 2000; 5: 199-228.
16. Huynh-Ba G, Pjeturrson BE, Sanz M, Cecchinato D, Ferrus J, Lindhe J, Lang NP. Analysis of the socket bone wall dimensions in the upper maxilla in relation to immediate implant placement. *Clin Oral Impl Res* 2010; 21: 37-42.
17. Belser U, Buser D, Higginbottom F. Consensus statements and recommended clinical procedures regarding esthetics in implant dentistry. *International Journal of Oral and Maxillofacial Implants* 2004; 19 (Suppl): 73-74.
18. Nevins M, Camelo M, De Paoli S, Friedland B, et al. A study of the fate of the buccal wall of extraction sockets of teeth with prominent roots. *Int J Perio and Restorative Dent* 2006; 26: 19-29.
19. Fickl S, Zuhr O, Wachtel H, Stappert CFJ, Stein JM, Hürzeler MB. Dimensional changes of the alveolar ridge contour after different socket preservation techniques. *J Clin Periodontol* 2008; 35: 906-913.
20. Cardaropoli D, Cardaropoli G. Preservation of the Postextraction Alveolar Ridge: A Clinical and Histologic Study. *Int J Perio and Restorative Dent* 2008; 28: 469-477.
21. Lekovic V, Camargo PM, Klokkevold PR, Weinlaender M, Kenney EB, Dimitrijevic B, and other. Preservation of alveolar bone in extraction sockets using bioabsorbable membranes. *J Periodontol* 1998; 69: 1044-1049.
22. Iasella JM, Greenwell H, Miller RL, Hill M, Drisko C, Bohra A, Scheetz JP. Ridge Preservation with Freeze-Dried Bone Allograft and a Collagen Membrane Compared to Extraction Alone for Implant Site Development: A Clinical and Histologic Study in Humans. *J Periodontol* 2003; 74: 990-999.
23. Tal H, Moses O. A comparison of panoramic radiography with computed tomography in the planning of implant surgery. *Dentomaxillofac Radiol* 1991; 20: 40-42.
24. Sukovic P. Cone beam computed tomography in craniofacial imaging. *Orthod Craniofacial Res* 2003; 6 (Suppl.1): 31-36.
25. Kobayashi K, Shimoda S, Nakagawa Y, Yamamoto A. Accuracy in Measurement of Distance Using Limited Cone-Beam Computerized Tomography. *Int J Oral Maxillofac Implants* 2004; 19: 228-231.
26. Bolin A, Eliasson S, von Beetzen M, Jansson L. Radiographic evaluation of mandibular posterior implant sites: correlation between panoramic and tomographic determinations. *Clinical Oral Implants Research* 1996; 7: 354-359.

27. Reddy MS, Mayfield-Donahoo T, Vanderven FJJ, Jeffcoat MK. A comparison of the diagnostic advantages of panoramic radiography and computed tomography scanning for placement of root form dental implants. *Clin Oral Impl Res* 1994; 5: 229-238.
28. Fuhrmann RAW, Bucker A, Diedrich PR. Assessment of alveolar bone loss with high resolution computed tomography. *J Periodont Res* 1995; 30: 258-263.
29. Hamada Y, Kondoh T, Noguchi K, Iino M, Isono H, Ishii H, Mishima A, Kobayashi K, Seto K. Application of Limited Cone Beam Computed Tomography to Clinical Assessment of Alveolar Bone Grafting: A Preliminary Report. *Cleft Palate Craniofac J* 2005; 42: 128-137.
30. Beck T, Mealy B. Histological Analysis of Healing Following Tooth Extraction with Ridge Preservation Using Mineralized Human Bone Allograft. *J Periodontol* 2010; 81: 1765-1772.
31. Akesson L, Hakansson J, Rohlin M. Comparison of panoramic and intraoral radiography and pocket probing for the measurement of the marginal bone level. *J Clin Periodontol* 1992; 19: 326-332.
32. Yang J, Lee H, Vernino A. Ridge preservation of dentition with severe periodontitis. *Compend Contin Educ Dent* 2000; 21: 579-583.

Table 1. Characteristics of a Study Population

Characteristic	Preserved Site (P)	Control Site (C)
Age (years)	54 (2.45)	64 (4.91)
Gender (n)		
Male	11 (55%)	2 (40%)
Female	9 (45%)	3 (60%)
Race (n)*		
Caucasian	18 (90%)	2 (40%)
African-American	2 (10%)	3 (60%)
Tooth Type (n)		
Upper Incisor	5 (25%)	2 (40%)
Upper Premolar	11 (55%)	1 (20%)
Lower Premolar	4 (20%)	2 (40%)
Extraction Reason (n)		
Periodontal Disease	4 (20%)	3 (60%)
Non-restorable Caries	16 (80%)	2 (40%)

*Significantly different between treatment groups p=0.037

Table 2. Initial Clinical and Radiographic Ridge Dimensions

Initial Ridge Dimensions	Preserved Site (P) (n=20)	Control Site (C) (n=5)
VMB (mm) Clinical (CVMB) Radiographic (RVMB)	10.80 (2.24) 10.82 (2.47)	11.80 (1.92) 12.28 (2.25)
VDB (mm) Clinical (CVDB) Radiographic (RVDB)	11.05 (2.61) 10.59 (2.52)	10.80 (1.79) 11.47 (2.62)
VML (mm) Clinical (CVML) Radiographic (RVML)	9.90 (2.02) 9.85 (2.35)	11.20 (3.11) 11.20 (3.12)
VDL (mm) Clinical (CVDL) Radiographic (RVDL)	9.90 (2.02) 10.11 (2.17)	10.40 (3.21) 10.73 (3.81)
VO (mm) Clinical (CVO) Radiographic (RVO)	18.55 (3.82) 18.21 (2.85)	18.00 (2.12) 17.79 (2.52)
B1 (mm) Clinical (CB1) Radiographic (RB1)	1.20 (0.83) 1.24 (0.54)	1.00 (0.00) 1.59 (0.44)
B5 (mm) Clinical (CB5) Radiographic (RB5)	1.88 (1.09) 1.52 (0.70)	1.60 (0.55) 1.78 (0.44)
BL1 (mm) Clinical (CBL1) Radiographic (RBL1)	9.95 (3.80) 9.29 (3.47)	9.00 (1.22) 9.39 (1.67)
BL5 (mm) Clinical (CBL5) Radiographic (RBL5)	11.50 (4.82) 9.79 (4.16)	10.40 (1.14) 10.49 (2.02)

Table 3a. Correlations between Clinical and Radiographic Measurements at Initial Appointment

Clinical Measurements	Radiographic Measurements	R Value*
CVMB	RVMB	0.89
CVDB	RVDB	0.89
CVML	RVML	0.90
CVDL	RVDL	0.91
CVO	RVO	0.87
CB1	RB1	0.37
CB5	RB5	0.54
CBL1	RBL1	0.92
CBL5	RBL5	0.89

*All values statistically significant $p=0.05$

Table 3b. Correlations between Clinical and Radiographic Measurements at Follow up Appointment (3-4 Months)

Clinical Measurements	Radiographic Measurements	R Value*
CVMB	RVMB	0.90
CVDB	RVDB	0.87
CVML	RVML	0.88
CVDL	RVDL	0.86
CVO	RVO	0.93
CBL1	RBL1	0.71
CBL5	RBL5	0.56

*All values statistically significant $p=0.05$

Table 4. Changes in Clinical and Radiographic Ridge Dimensions over 3-4 Months

Changes in Ridge Dimensions (Three month - Initial)	Preserved Site (P) (n=20)	Control Site (C) (n=5)
VMB (mm)		
Clinical (CVMB)	-0.30 (1.30)	0.80 (0.45)
Radiographic (RVMB)	-0.17 (1.51)	0.35 (0.86)
VDB (mm)		
Clinical (CVDB)*	-0.65 (1.18)	0.60 (1.14)
Radiographic (RVDB)	0.12 (1.45)	0.90 (0.98)
VML (mm)		
Clinical (CVML)	0.00 (0.97)	-0.20 (1.79)
Radiographic (RVML)	0.61 (1.33)	0.03 (1.63)
VDL (mm)		
Clinical (CVDL)	0.40 (1.35)	0.40 (1.14)
Radiographic (RVDL)	0.38 (1.38)	1.41 (0.49)
VO (mm)		
Clinical (CVO)	-9.30 (3.79)	-5.60 (3.51)
Radiographic (RVO)**	-8.96 (3.13)	-4.95 (1.60)
B1 (mm)		
Clinical (CB1)	N/A	N/A
Radiographic (RB1)	-0.31 (0.40)	-0.66 (0.28)
B5 (mm)		
Clinical (CB5)	N/A	N/A
Radiographic (RB5)	-0.25 (0.59)	-0.25 (0.19)
BL1 (mm)		
Clinical (CBL1)	-0.40 (3.55)	-2.40 (1.52)
Radiographic (RBL1)	-0.16 (3.32)	-1.26 (0.79)
BL5 (mm)		
Clinical (CBL5)	0.25 (4.40)	-1.80 (1.10)
Radiographic (RBL5)	0.63 (3.92)	-0.71 (0.65)

*Significantly different between treatment groups p=0.044

**Significantly different between treatment groups p=0.01

Table 5. Initial and Change over 3-4 Months in Radiographic Vertical Occlusal Dimension Based on Reason for Extraction.

Radiographic Vertical Occlusal Measurement	Preserved Site (P) (n=20)	Control Site (C) (n=5)
RVO Initial (mm)		
Non-Restorable Caries	18.61 ± 2.89 (n=16)	15.94 ± 0.14 (n=2)
Periodontal Disease	16.62 ± 2.31 (n=4)	19.02 ± 2.65 (n=3)
Change in RVO (mm)		
Non-Restorable Caries*	-9.89 ± 2.50 (n=16)	-6.00 ± 2.56 (n=2)
Periodontal Disease	-5.26 ± 2.80 (n=4)	-4.25 ± 0.16 (n=3)

*Significantly different between treatment groups p=0.05

Figure 1. Clinical Measurements

a. External Vertical Dimensions/Ridge Height Measurements; b. Internal Vertical Dimension/Internal Socket Measurement; c. Internal Vertical Dimension/Internal Socket Measurement; d. Horizontal Dimension/Ridge Width Measurement at Crest; e. Horizontal Dimension/Ridge Width Measurement 5 mm below Crest

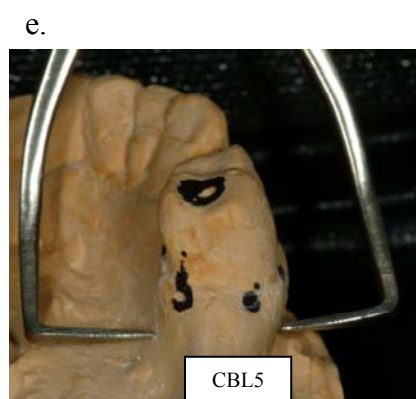
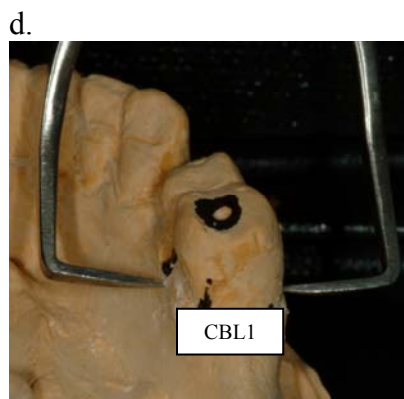
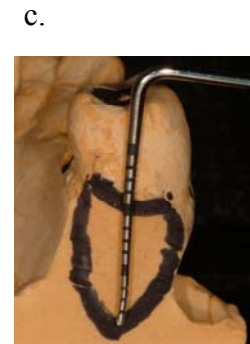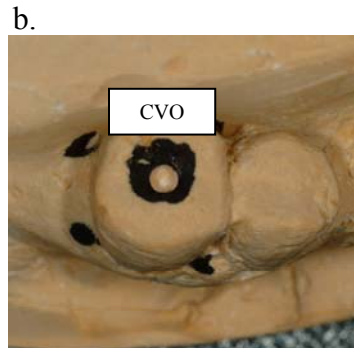
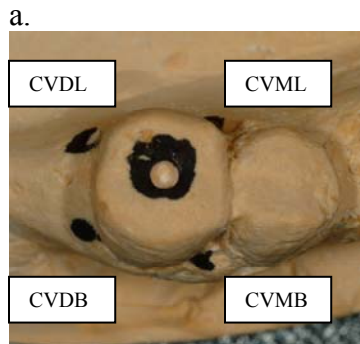

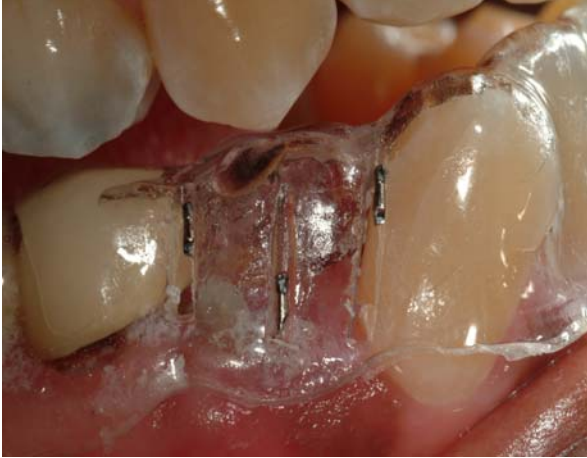
Figure 2. Clinical Measurements Represented on the Stent

a. Buccal View; b. Lingual View

a.

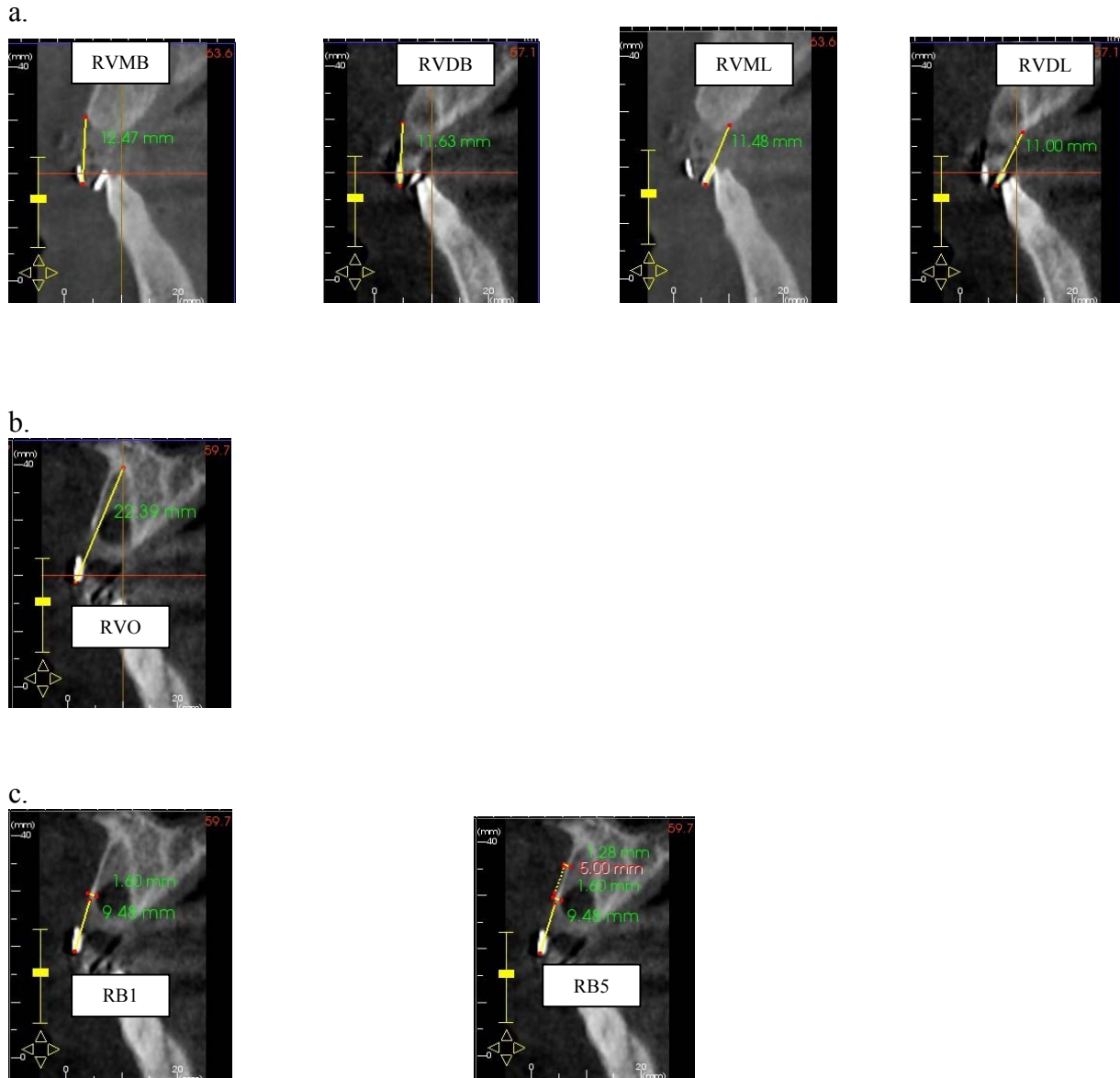


b.

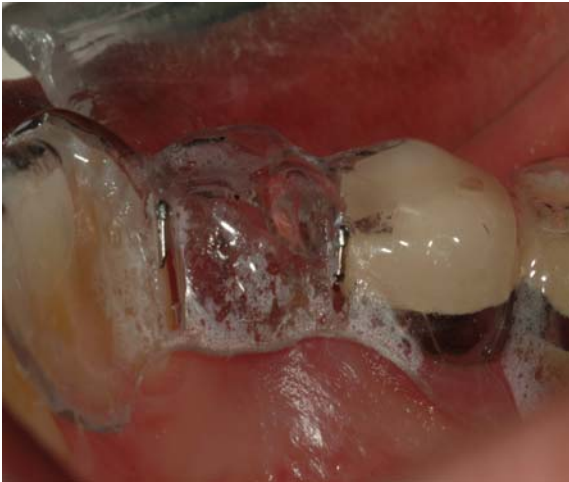

Figure 3. Radiographic Measurements.

- a. External Vertical Dimensions/Ridge Height Measurements;
- b. Internal Vertical Dimension/Internal Socket Measurement;
- c. Horizontal Dimension/Buccal plate at Crest and 5 mm below Crest;
- d. Horizontal Dimension/Ridge Width Measurement at Crest and 5 mm below Crest



d.

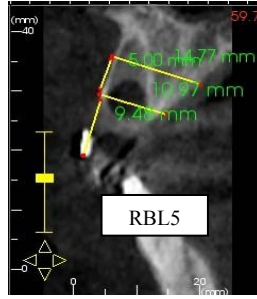
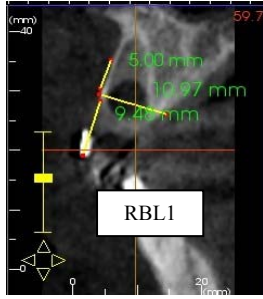


Figure 4. Surgical Protocol of Preserved Sites (P)

a. Non-restorable caries #13; b. Extraction #13; c. Freeze-dried human allograft placed in extraction site; d. Bioabsorbable collagen membrane placed over bone graft; e. Figure-8 horizontal mattress sutures; f. 3 month follow up with implant placement

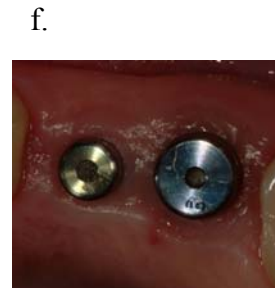
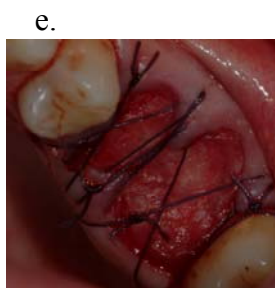
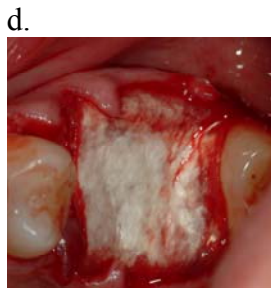
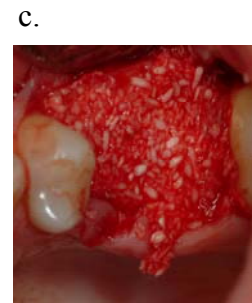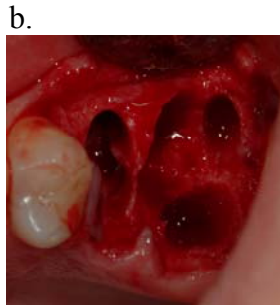

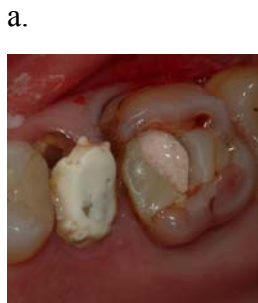
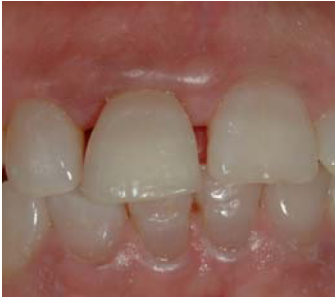Figure 5. Surgical Protocol of Control Sites (C)

a. Periodontally diseased #8; b. Extraction with collagen plug and figure-8 suture

a.



b.

